

Non-Sustained Polymorphic Ventricular Tachycardia Following Modified Valsalva Maneuver: A Case Report

Jose Nunes de Alencar Neto*, Saulo Rodrigo Ramalho de Moraes, Julimar Medeiros Neves, Pedro Felipe Prates Silva

Hospital Sao Paulo, Sao Paulo, Brazil

*Corresponding author: Jose Nunes de Alencar Neto, Borges Lagoa Street, 1209, Postal Code: 04038-033, Vila Mariana, Sao Paulo, Brazil, E-mail: josenunesalencar@gmail.com

Received Date: June 12, 2017 Accepted Date: July 05, 2017 Published Date: July 07, 2017

Citation: Jose Nunes de Alencar Neto (2017) Non-Sustained Polymorphic Ventricular Tachycardia Following Modified Valsalva Maneuver: A Case Report. Case Reports: Open Access 1: 1-4.

Abstract

Vagal maneuver is considered as the first step in treatment of stable supraventricular tachycardias with good safety. We present a case where an otherwise healthy 47 year old woman presenting supraventricular tachycardia had non-sustained polymorphic ventricular tachycardia following the modified Valsalva maneuver. To our knowledge, this is the second case in literature presenting this complication and the first with the new modified method.

Keywords: Ventricular; Tachycardia; Valsalva; Maneuver

Introduction

The modified Valsalva maneuver is a safe method to termination of supraventricular tachycardias in emergency rooms [1]. It is considered as a safe procedure and constitutes the first step to treat these cases. It is different from traditional maneuver since the patient is lied down and has his legs lifted after 15 seconds of forced expiration [2].

Case Report

A 47-year-old woman presented with palpitations that began 50 minutes before arrival at our hospital. She had no previous disease and was not using any continuous medication. A 12-lead electrocardiogram showed a narrow QRS-complex tachycardia at a rate of 176 beats per minute (Figure 1). Retrograde P waves were visible as negative inscriptions in DII with a RP of 80ms. Patient was hemodynamically stable and modified vagal maneuver was performed.

With continuous recording at a DII long-strip, the patient, positioned at 45°, was told to do forced expiration to against a 10cc syringe for 15 seconds, then the patient is immediately laid flat and had her legs raised to 45° for 15 seconds.

When the patient was lied down and her legs were lifted, a non-sustained ventricular polymorphic tachycardia was initiated without a preceding bradycardic rhythm with posterior spontaneous termination of the tachycardia to sinus rhythm (Figure 2). A 12-lead electrocardiogram was then performed, with normal conduction system, normal QT interval and no visible pre-excitation.

Transthoracic echocardiogram was normal. The patient was submitted to electrophysiological study, finding of a concealed accessory pathway, successfully ablated. Decremental and programmed ventricular stimulation did not induce tachycardias.

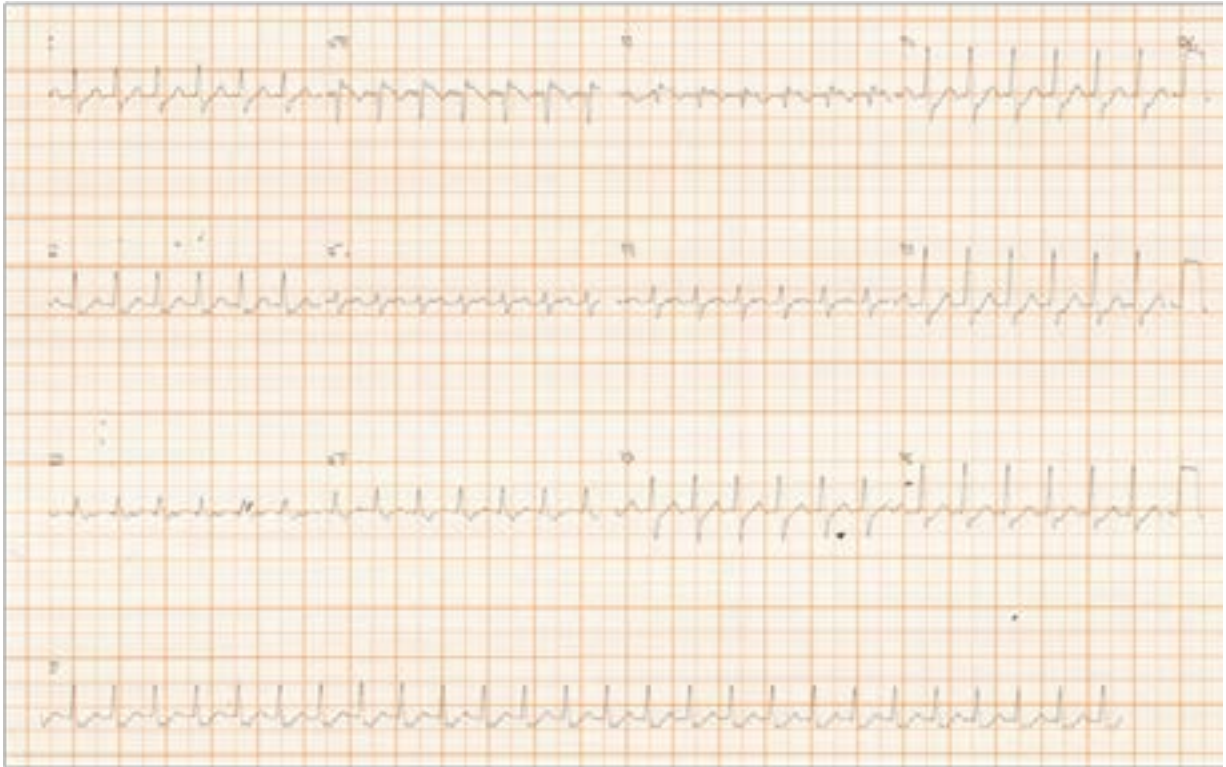

Figure 1: Narrow QRS-complex tachycardia at a rate of 176 b.p.m. Retrograde p waves are observable as negative inscriptions 80ms after beginning of QRS.

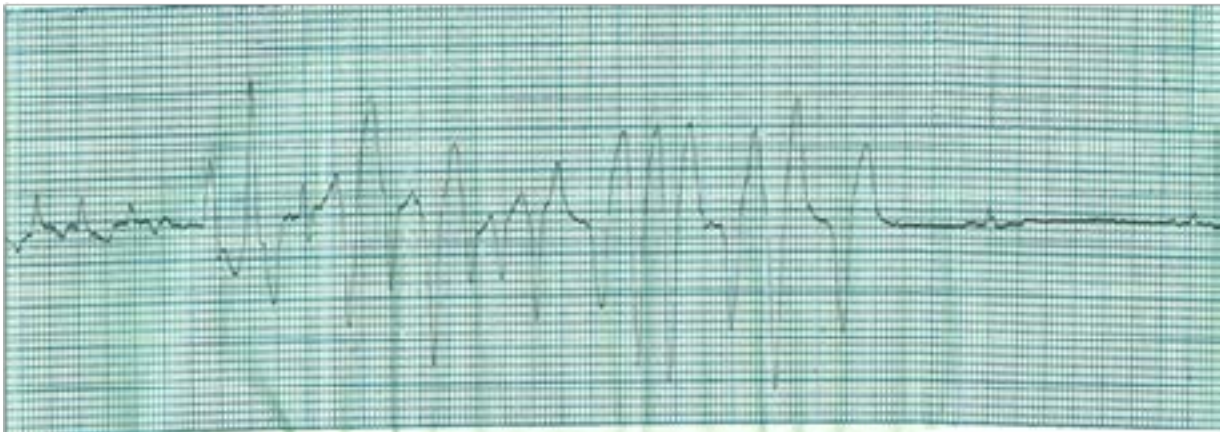


Figure 2: Non-sustained polymorphic ventricular tachycardia following modified Valsalva maneuver.

Discussion

Transthoracic echocardiogram was normal. The patient was submitted to electrophysiological study, with finding of a concealed accessory pathway, successfully ablated. Decremental and programmed ventricular stimulation did not induce tachycardias.

SVT is recognized in a 12-lead ECG performed during tachycardia for a narrow QRS and a regular rhythm [1]. In cases of large QRS (>120ms), it may be a SVT as well, but the diagnosis of Ventricular Tachycardia (VT) is imposed. Atrioventricular dissociation, concordance of the precordial QRS, a more pronounced delay in the initial portion of the QRS than in the last portion, among others, may suggest a VT as mechanism [5-7].

When a narrow-QRS tachycardia is present, one of the possibilities is the presence of a reentrant tachycardia which uses the Atrioventricular Node (AVN) as one limb of the circuit. In cases of reentrant SVT, a retrograde P wave may be visible in a 12-lead ECG. In typical Atrioventricular Node Reentrant Tachycardia (AVNRT), the anterograde limb of the circuit is the slow pathway of the AVN and the retrograde limb is the fast pathway. The retrograde P wave in AVNRT is nearly simultaneous with the QRS, so the terminal portion of the P wave may appear as part of the QRS components, such as a pseudo S wave in inferior leads or a pseudo R' wave in V1 and in majority of cases no longer than 70ms after the beginning of the QRS complex. In Atrioventricular Reentrant Tachycardia (AVRT), one of the limbs of the circuit is an accessory pathway. The retrograde P wave may usually be seen in the initial portion of the ST-T segment, usually more than 100ms after the beginning of the QRS. Since the AVNRT and the AVRT, when typical, present with retrograde P waves nearby the QRS complex, they are called short-RP tachycardias, but the distance from the beginning of the QRS and the beginning of the retrograde P wave might be useful for the differential diagnosis [8,9].

Acute treatment of SVT in emergency departments shall begin with vagal maneuvers as first line intervention. There is no gold standard for proper vagal maneuver technique in the current Guidelines, but in our service, we prefer modified Valsalva maneuver as it is safer than carotid sinus massage and more efficient than standard Valsalva maneuver. These maneuvers typically will not be effective if the arrhythmia does not involve the AVN as a requisite component of the reentrance.

Valsalva maneuver is a technique where a person in supine position breathes against a resistance of 40mmHg for 15 seconds. A vagal bradycardia reflex is stimulated and a decreased conductance through the AVN may terminate the tachycardia if at least of the limbs is located there [10]. Modified Valsalva maneuver was tested in a non-blinded randomized trial to test its efficacy against standard maneuver [2]. With 433 patients enrolled, the REVERT trial evidenced 43% of success in reverting to sinus rhythm in the group performing modified maneuver against only 17% in control group ($p < 0.0001$). No serious adverse events were recorded.

The technique is to stay in semi-recumbent (45°) position on a trolley than a forced expiration of 40mmHg is performed during 15 seconds and, at the end of the strain, the patient is laid flat and have its legs risen by a member of the staff to 45° for 15 seconds. An adaptation of the technique is used in our service: the patient has to blow a 10cc syringe just to move the plunger. This adaptation is suggested by the authors of the trial and generates a similar pressure.

There are few reports of arrhythmic complications of vagal maneuvers in modern literature: onset of ventricular arrhythmias in patient with previous ischemic heart disease and left ventricular dysfunction [11] and ventricular fibrillation during carotid sinus massage in a previously healthy 76-year-old man and no history of ischemic heart disease [12]. The last case is supposed to be caused by augmented sympathetic tone due to the rebound effect of vagal maneuvers. One case of polymorphic ventricular tachycardia in an otherwise healthy man after Valsalva maneuver has been published [13] and, like ours, was also not related to bradycardia, changes in QT interval or a short-long-short interval.

Conclusion

To our knowledge, this is the second case of non-sustained polymorphic ventricular tachycardia following Valsalva maneuver, and the first after the modification of its methodology. This and the other cases support the need of resuscitation equipment when these maneuvers are proposed.

References

- 1) Page RL, Joglar JA, Caldwell MA, Calkins H, Conti JB, et al. (2015) 2015 ACC/AHA/HRS guideline for the management of adult patients with supraventricular tachycardia. *Circulation* 2015 Sep 23..
- 2) Appelboom A, Reuben A, Mann C, Gagg J, Ewings P, et al. (2015) Postural modification to the standard Valsalva manoeuvre for emergency treatment of supraventricular tachycardias (REVERT): a randomised controlled trial. *Lancet* 386:1747-1753.
- 3) Orejarena LA, Vidaillet H Jr, DeStefano F, Nordstrom DL, Vierkant RA, et al. (1998) Paroxysmal supraventricular tachycardia in the general population. *J Am Coll Cardiol* 31: 150-157.
- 4) Gonzalez-Torrecilla E, Almendral J, Arenal A, Atienza F, Atea LF, et al. (2009) Combined evaluation of bedside clinical variables and the electrocardiogram for the differential diagnosis of paroxysmal atrioventricular reciprocating tachycardias in patients without pre-excitation. *J Am Coll Cardiol* 53: 2353-2358.
- 5) Brugada P, Brugada J, Mont L, Smeets J, Andries EW (1991) A new approach to the differential diagnosis of a regular tachycardia with a wide QRS complex. *Circulation* 83: 1649-1659.
- 6) Vereckei A, Duray G, Szenasi G, Altemose GT, Miller JM (2008) New algorithm using only lead aVR for differential diagnosis of wide QRS complex tachycardia. *Heart Rhythm* 5: 89-98.
- 7) Vereckei A (2014) Current algorithms for the diagnosis of wide QRS complex tachycardias. *Curr Cardiol Rev* 10: 262-276.
- 8) de Luna AB (2011) *Clinical Arrhythmology*. 3rd edition, John Wiley & Sons..
- 9) Issa Z, Miller JM, Zipes DP (2012) *Clinical arrhythmology and electrophysiology: A Companion to Braunwald's Heart Disease*. 2nd edition, Elsevier Health Sciences, Philadelphia.
- 10) Wong LF, Taylor DM, Bailey M (2004) Vagal response varies with Valsalva maneuver technique: a repeated-measures clinical trial in healthy subjects. *Ann Emerg Med* 43: 477-482.
- 11) Fox M, Verga T, Jadonath R, Beldner S (2008) Pause dependent ventricular tachycardia resultant from carotid sinus massage. *PACE-Pacing Clin Electrophysiol* 31: 389-390.
- 12) Deepak SM, Jenkins NP, Davidson NC, Bennett DH, Mushahwar SS (2005) Ventricular fibrillation induced by carotid sinus massage without preceding bradycardia. *Europace* 7: 638-640.
- 13) De Mattia L, Brieda M, Del Bianco F, Dametto E, Nicolosi GL (2012) Polymorphic ventricular tachycardia induced by Valsalva manoeuvre in a patient with paroxysmal supraventricular tachycardia. *Europace* 14: 767-768.

Submit your manuscript to a JScholar journal and benefit from:

- Convenient online submission
- Rigorous peer review
- Immediate publication on acceptance
- Open access: articles freely available online
- High visibility within the field
- Better discount for your subsequent articles

Submit your manuscript at
<http://www.jscholaronline.org/submit-manuscript.php>