

## A Novel Stop Codon Variant of *ADAMTS10* Gene in Weill-Marchesani Syndrome

Ozcan AA<sup>1</sup>, Ulas B<sup>2</sup>, Boga I<sup>3,4</sup>, Bisgin A<sup>\*3,4</sup>

<sup>1</sup>Cukurova University Faculty of Medicine, Ophthalmology Department, Adana, TURKEY

<sup>2</sup>Baskent University Adana Medical and Research Center, Ophthalmology Department, Adana, TURKEY

<sup>3</sup>Cukurova University AGENTEM (Adana Genetic Diseases Diagnosis and Treatment Center), Adana, Turkey

<sup>4</sup>Cukurova University Faculty of Medicine, Department of Medical Genetics, Adana, Turkey

\*Corresponding author: Bisgin A, Cukurova University Faculty of Medicine, Medical Genetics Department of Balcali Hospital and Clinics & Cukurova University AGENTEM (Adana Genetic Diseases Diagnosis and Treatment Center), Adana, Turkey. Tel: +90-532-5652167, E-mail: abisgin@yahoo.com

Received Date: February 13, 2022 Accepted Date: February 14, 2022 Published Date: March 28, 2022

Citation: Ozcan AA, Ulas B, Boga I, Bisgin A, (2022) A Novel Stop Codon Variant of *ADAMTS10* Gene in Weill-Marchesani Syndrome. J Ophthalmol Open Access 6: 1-6.

### Abstract

Weill-Marchesani syndrome is a rare genetic disorder presenting microspherophakia, high myopia, secondary glaucoma, and systemic abnormalities. Even though, clinical evaluation is the main diagnosis criteria, genetic testing become an obligatory to confirm diagnosis. Here we share a 9-year-old male patient of an advanced glaucoma with an intraocular pressure of 45 mmHg in the both eyes. Slit lamp examination through the pupil revealed a dislocated microspherophakic lens causing pupillary block and the anterior chambers were quite shallow. A microspherophakic lens was confirmed by anterior segment optical coherence tomography. Weill-Marchesani syndrome was then diagnosed by ocular examinations, and was accompanied by systemic abnormalities, including brachymorphia and brachydactyly. In our case, *ADAMTS10* gene sequencing was performed to confirm the diagnosis. The patient subsequently received bilateral YAG laser peripheral iridotomy to control the intraocular pressure. At the 1-year follow-up visit, the patient had well-controlled intraocular pressure, transparent cornea, while the lens remained correctly in place. Molecular analysis revealed that the patient had a novel homozygous c.2486G>A (p.W829\*) variant in *ADAMTS10* gene.

**Key words:** Weill-Marchesani Syndrome, *ADAMTS10* Gene, Rare Disease, Genetic Diagnosis

## Introduction

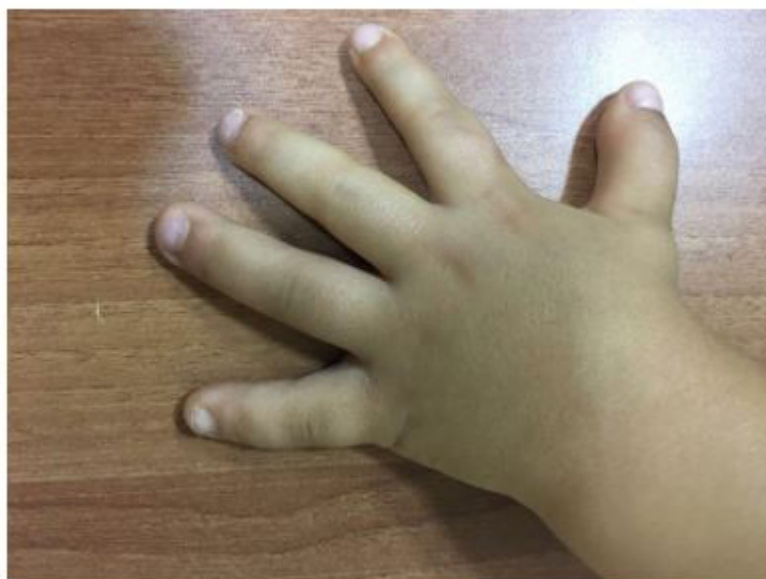Weill-Marchesani syndrome (WMS), also known as microspherophakia-brachydactyly syndrome, is a genetic and rare connective tissue disorder [1]. WMS is characterized by short stature, brachydactyly, thick skin, mild mental retardation, cardiac anomalies, joint stiffness, lens microspherohakia, lens luxation, high myopia, glaucoma and corneal changes [1,2]. WMS have a high incidence of secondary glaucoma and recurrent glaucoma attacks will lead to angle adhesion and trabecular meshwork damage [3].

The disease presents both autosomal dominant and autosomal recessive inheritance modalities via different genes. Despite genetic heterogeneity, disease exhibit clinical homogenous features [4]. The disease inherited mostly as an autosomal recessive trait due to disease causing alterations of the *ADAMTS10* gene [4]. The ADAMTS (a disintegrin-like and metalloproteinase domain with thrombospondin-type 1 motifs) protein family secreted by metalloproteinases include 19 enzymes, which are involved in several physiological and pathological processes [5, 6]. *ADAMTS10* gene involves to the secretory pathway during post-translational modification [6]. The manifestations of *ADAMTS10* gene disorders in humans suggested that they participated in the structural and regulatory roles of microfibrils. [4, 6]. *ADAMTS10* is expressed in skin, fetal chondrocytes, and fetal and adult heart. [4, 6]. To date, clinically related missense variations,


non-sense variants, splice site variants have been reported for the *ADAMTS10* gene [4, 6]. Here we report a new non-sense variant of the *ADAMTS10* gene in a young patient with Weill-Marchesani syndrome.

## Clinical Report

A-9-year-old male patient referred with a 9-month-old history of ocular pain and blurred vision in both eyes with redness. There was no history of ocular abnormalities in family members. The best corrected visual acuity was 3/10 in the right eye and 4/10 in the left eye with high lenticular myopic and astigmatic correction. Corneal edema was present and also peripheral shallowing of the anterior chamber was seen in both eyes. The right and left pupil was fixed and half dilated. The intraocular pressure was 45 mmHg in the both eyes. Slit lamp examination revealed a small globular lens, microspherophakia with stretched zonules causing anterior subluxation resulting pupillary block and shallow anterior chamber. Gonioscopy showed grade 2 angles with no peripheral anterior synechia in the both eyes. Extended-depth SD-OCT demonstrated microspherophakic lenses with lenticular iris contact and anteriorly displaced irides in association with shallow anterior chambers (Figure 1). The fundus examination was normal except glaucomatous cupping of optic nerves (C/D 0.5-0.6) in both eyes. On systemic examination, he had brachydactyly, joint stiffness and brachymorphia (Figure 2). After ocular and systemic examination, Weill-Marchesani syndrome was diagnosed.



**Figure 1:** SD-OCT demonstrated microspherophakic lenses with lenticular iris contact and anteriorly displaced irides in association with shallow anterior chambers




**Figure 2:** Patient had brachydactyly on systemic examination

Bilateral peripheral Nd:Yag iridotomies were performed to relieve associated pupillary block. In the both eyes, angles were open but narrow after iridotomy. The patient was followed up regularly for intraocular pressure and fundus evaluation. On follow up at 1-year, the patient had well-controlled intraocular pressure, open peripheral iridectomy, transparent cornea, while the lens remained correctly in place.

While the diagnosis of Weill-Marchesani syndrome is a clinical one, genetic tests is crucial to confirm the diagnosis. Therefore, genetic testing of *ADAMTS10* gene carried out via next generation sequencing. Peripheral blood sample were obtained for DNA isolation performed by using the QIAamp DNA Blood Mini Kit (Qiagen, Germany), according to the manufacturer's instructions. The quality of the DNA samples was assessed with the Qubit™ Fluorometric Quantitation system (Thermo Fisher Scientific, USA). Next generation sequencing was performed for *ADAMTS10* gene including all exons and exon-intron junctions via Illumina Miseq platform to detect disease related variants. Briefly, isolated genomic DNA was enriched by PCR (Polymerase Chain Reaction) in order to sequence targeted regions in *ADAMTS10* gene. Then samples tagged with sample specific barcodes and libraries prepared for sequencing step. Quality control had been done at the end of library preparation

by capillary gel electrophoresis. At the end of workflow, prepared libraries next generation sequenced with MiSeq Next Generation System (Illumina, California, USA). The raw data and QC of sequenced data were evaluated before variant interpretation. Eligible sequencing data went through variants analysis by using QCI-A software (Qiagen, Hildenberg, Germany). Bioinformatics analyses had been performed for all detected variants in QCI-I bioinformatics tool. Various databases and in-silico tools were used during interpretations such as the HGMD, 1000 Genome Frequency and Ingenuity Knowledge Base databases and CADD, PolyPhen, SIFT, Mutation Taster, BLOSUM, PhyloP, MaxEntScan, GeneSplicer, B-SIFT, QCI Inferred Activation in-silico predictions tools.

Molecular genetic testing revealed that the patient had c.2486G>A (p.W829\*) (p.Trp829\*) (Homozygous) variant in 21st exon of *ADAMTS10* (NM\_030957) gene (Figure 3). The detected non-sense variant has not been reported previously in any database and it was defined as a previously unreported novel variant while *ADAMTS10* gene is related with the Weill-Marchesani syndrome. In this case, variant was considered to be the most likely cause of the disease being early stop codon and has evidence of PVS1, PM2 and PP3 according to ACMG criteria. The patient's parents demonstrated normal cytogenetic examination and crystalline lens morphology.



**Figure 3:** Sequence view of detected homozygous variant in *ADAMTS10* gene

## Discussion

Weill-Marchesani syndrome is a multisystem disease that affect skin, bones and joints, heart and eyes. This syndrome is characterized by short stature, joint stiffness, brachydactyly, and ocular anomalies including microspherophakia, myopia, ectopia lentis, cataract, and glaucoma [1,4], [7-9] Weill-Marchesani syndrome is also known as microspherophakia-brachydactyly syndrome. [3,8] The phenotype of our patient is compatible with Weill-Marchesani syndrome. Our case demonstrated microspherophakia, high myopia, glaucoma, and systemic abnormalities, including short stature and brachydactyly.

In spite of the clinical homogeneity, two modes of inheritance have been reported Weill-Marchesani syndrome, autosomal dominant and autosomal recessive. [8,9] Although autosomal dominant Weill-Marchesani syndrome is caused due to in the fibrillin 1 (*FBN1* gene), autosomal recessive WMS results due to disease-causing variant in the *ADAMTS10* gene and the latent transforming growth factor-beta-binding-protein 2 (*LTBP2* gene), which demonstrates genetic heterogeneity in this disease. [9,10] *ADAMTS10* gene related Weill-Marchesani syndrome is inherited in an autosomal recessive manner. [5,6,10] The parents of child with autosomal recessive Weill-Marchesani syndrome are obligate heterozygotes and therefore carry one mutated allele. [5,10,9,6] Functional variants in *ADAMTS10* are associated with Weill-Marchesani syndrome. [6] Missense variants, non-sense variants and splice site variants have been reported for

the *ADAMTS10* gene until today. [10,6] We identified a novel homozygous non-sense variant (c.2486G>A, p.W829\*), of the *ADAMTS10* gene in our case.

Weill Marchesani syndrome cases have a high incidence of secondary glaucoma, resulting in chronically increased intra-ocular pressure. [2,3] The visual prognosis is dominated by secondary glaucoma due to pupillary blockage by the mobile lens. [3,7] Angle closure in Weill-Marchesani syndrome and response to laser iridotomy and treatment with either miotic or cycloplegic agents may be complex [1-3] And this response depends on the relative proportion of pupillary block as a mechanism underlying the angle closure, the functional status of the zonular apparatus, and the degree of angle crowding by the peripheral iris in the presence or absence of peripheral anterior synechiae. [1,3,7] Surgical removal of the lens to control the glaucoma may ultimately be the option, but this procedure can be hazardous with vitreous loss and other complications to be expected. [1-3,7] In this disease, medical treatment of glaucoma is difficult because of paradoxical response to miotics and mydriatics. [1-3] Surgical management of glaucoma in Weill-Marchesani syndrome can include peripheral iridectomy to prevent or relieve pupillary block and trabeculectomy in advanced chronic angle closure glaucoma. [1-3] Extended depth SD-OCT can be used to image the entire crystalline lens through the pupil, and may be useful in defining mechanisms of angle closure [7]. In our patient, extended depth SD-OCT imaging enabled visualization of the entire crystalline lens, which helped to elucidate mechanism of the

angle closure in both eyes. The microspherophakia of our case provided good explication for the high myopia, narrow anterior chamber and glaucoma. The increased lens curvature results in a narrow anterior chamber angle, and the lens moves forward because of zonular relaxation, which leads to pupillary block and elevated intraocular pressure. [1-3] Our patient's intraocular pressure was well controlled after peripheral iridectomy. Our patient has been followed up, and currently his both eyes were stable condition. At a 1-year follow up visit, the intraocular pressure was 13-14 mmHg in both eyes with clear cornea.

Weill- Marchesani syndrome is a rare disorder and clinicians should be aware of the patient's clinical presenting and molecular genetic testing for new disease-causing variants due to the heterogeneity of the disease. In this case, we reported a novel stop codon variant, c.2486G>A (p.W829\*) (Homozygous), of the *ADAMTS10* gene in a patient who met WMS clinical findings. Moreover, additional studies to define specific disease-causing variants of *ADAMTS10* gene still carries its importance.

## Ethics Approval and Consent to Participate

The parents of participant were informed, and signed consent/permissions for this research in accordance with Helsinki declaration.

## Acknowledgments

We would like to thank the editorial board of "Journal of Ophthalmology" for their review. We also thank to enrolled patients and individuals for participation.

## Conflict of Interest Statement

The authors declare no conflict of interest.

## Funding

This research received no external funding.

## References

1. Chung JL, Kim SW, Kim JH, Kim TI, Lee HK, Kim EK, (2007) A case of Weill-Marchesani syndrome with inversion of chromosome 15. *Korean journal of ophthalmology : KJO.* 21:255-60.
2. Evreklioglu C, Hepsen IF, Er H, (1999) Weill-Marchesani syndrome in three generations. *Eye (London, England).* 13:773-77.
3. Guo H, Wu X, Cai K, Qiao Z, (2015) Weill-Marchesani syndrome with advanced glaucoma and corneal endothelial dysfunction: a case report and literature review. *BMC ophthalmology.* 15:3.
4. Gallagher K, Salam T, Sin B, Gupta S, Zambarakji H, (2011) Retinal vascular tortuosity in a patient with weill-marchesani syndrome. *Case reports in ophthalmological medicine.* 952543.
5. Cain SA, Mularczyk EJ, Singh M, Massam-Wu T, Kielty CM (2016) ADAMTS-10 and -6 differentially regulate cell-cell junctions and focal adhesions. *Scientific reports* 6, 35956.
6. Steinkellner H, Etzler J, Gogoll L, Neesen J, Stifter E, Brandau O, Laccone F (2015) Identification and molecular characterisation of a homozygous missense mutation in the ADAMTS10 gene in a patient with Weill-Marchesani syndrome. *European journal of human genetics : EJHG* 23:1186-91.
7. Cabot F, Ruggeri M, Saheb H, Parel JM, Parrish RK (2014) Extended-depth spectral-domain optical coherence tomography imaging of the crystalline lens in Weill-Marchesani-like syndrome. *JCRS online case reports* 2:92-95.
8. Roszkowska AM, Aragona P (2011) Corneal microstructural analysis in weill-marchesani syndrome by in vivo confocal microscopy. *The open ophthalmology journal* 5:48-50.
9. Shah MH, Bhat V, Shetty JS, Kumar A (2014) Whole exome sequencing identifies a novel splice-site mutation in ADAMTS17 in an Indian family with Weill-Marchesani syndrome. *Molecular vision* 20:790-96.
10. Dagoneau N, Benoist-Lassel C, Huber C, Faivre L, Mégarbané A, Alswaid A, Dollfus H, Alembik Y, Munnich A, Legeai-Mallet L, Cormier-Daire V (2004) ADAMTS10 mutations in autosomal recessive Weill-Marchesani syndrome. *American journal of human genetics* 75L:801-06.

**Submit your manuscript to a JScholar journal and benefit from:**

- § Convenient online submission
- § Rigorous peer review
- § Immediate publication on acceptance
- § Open access: articles freely available online
- § High visibility within the field
- § Better discount for your subsequent articles

Submit your manuscript at  
<http://www.jscholaronline.org/submit-manuscript.php>