

Describe the Novel & Convenient Technique for the Insertion of Double J Stent after Laparoscopic Ureterolithotomy – How I Do It

Bo-Han Chen^{1,2}, Chien-Chang Kao², En Meng², Tai-Lung Cha², Guang-Huan Sun², Dah-Shyong Yu² and Sheng-Tang Wu^{2*}

¹Division of Urology, Department of Surgery, Taoyuan Armed Forces General Hospital, Taoyuan, Taiwan, ROC

²Division of Urology, Department of Surgery, Tri-Service General Hospital, National Defense Medical Center, Taipei, Taiwan, ROC

*Corresponding author: Sheng-Tang Wu, M.D., Division of Urology, Department of Surgery, Tri-Service, General Hospital, No. 325, Cheng-Kung Rd, Sec 2, Neihu 114, Taipei, Taiwan, Tel: 886-2-8792-7191, Fax: 886-2-8792-7372, E-mail: doc20283@gmail.com

Received Date: October 24, 2021 Accepted Date: November 24, 2021 Published Date: November 26, 2021

Citation: Bo-Han Chen (2021) Describe the Novel & Convenient Technique for the Insertion of Double J Stent after Laparoscopic Ureterolithotomy – How I Do It. J Surg Proce Case Rep 3: 1-4.

Abstract

To describe a new step-by-step technique to facilitate the insertion of double -J stent after laparoscopic ureterolithotomy. Use of the novel technique for insertion of double-J stent during laparoscopic ureterolithotomy is simple and easy. It provided good surgical results in our experience.

Keywords: Novel Technique; Ureterolithotomy; Laparoscopy; Double -J

Introduction

Laparoscopic ureterolithotomy (LU) is an alternative treatment for a large impacted ureteral stone or as salvage therapy when ureteroscopic removal of a stone or extracorporeal shock wave lithotripsy has failed [1,2]. Prolonged urine leakage and ureteral stricture have been the main postoperative complications. In a review of published literature, double J (D-J) stent insertion has been used to prevent these complications [3-5]. In this present article, we describe the detailed new technique procedure for facilitating the insertion of a D-J stent into the ureter after LU. This technique is a specific modification not described previously.

Material and Methods

Between January 2010 and December 2019, sixty patients who had undergone LU used this new and easy technique to introduce a D-J stent into the ureter. We used two metal stents passing through the side hole of D-J stent to straighten it. The choosing position of side holes was depended on the location of ureteral stone, including upper third or middle third (Figure 1). After identifying the ureter and removing the ureteral stone, a modified D-J stent was pushed into peritoneal cavity and then kept within ureter finally.

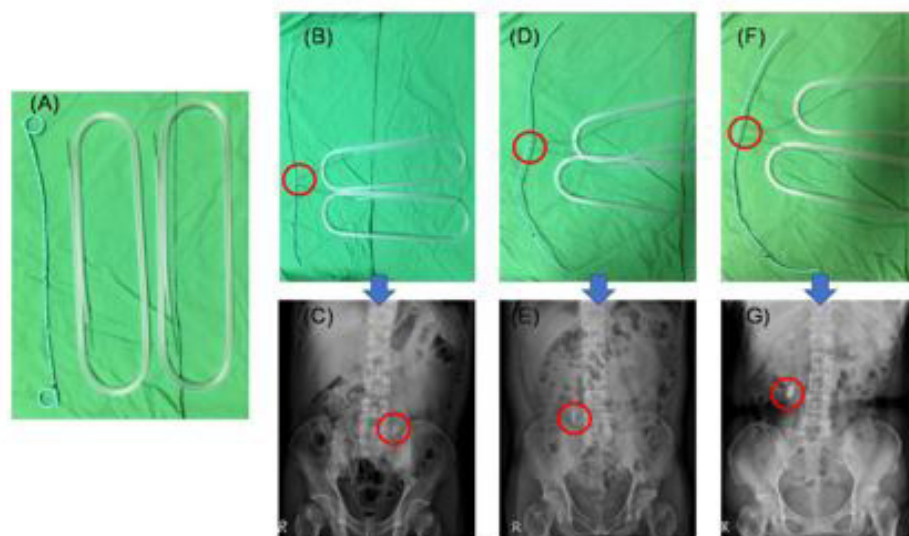


Figure 1: 1A: we used a 7-Fr × 26-cm D-J stent and two metal guidewires to fabricate our modified D-J stent system. 1B & 1C: designed for middle ureteral stone. 1D & 1E and 1F & 1G: designed for upper ureteral stone

Surgical procedure

Position and Incision: Those patients were placed with lateral decubitus position. Then, we made one 10mm trocar wound to inflate the abdominal cavity, then camera was inserted. Another 5mm and 10 mm trocars was also penetrated into abdominal cavity for working instruments.

Ureter isolation and localization of ureteral stone: First, the colon was taken down, then the ureter was identified. Second, we made a ureterostomy by scissor over the stone site, and we used the laparoscopic stone forcep or dissector to remove ureteral stone (Figure 2A).

Technique of insertion of ureteral double J stent (D-J)

The modified D-J stent was pushed into peritoneal cavity via trocar, then metal stents were kept outside (Figure 2B). We first use two laparoscopic forceps to hold the end of a modified D-J stent and pass it through the ureterostomy site into the bladder. Then, we pull out the metal guidewire, leaving the terminal curl of D-J stent in the bladder. The other end of the D-J stent is then passed through the same ureterostomy site into the renal pelvis, and the metal guidewire is pulled out (Figure 3). We adjust the location of the D-J stent in the ureter, and then suture the ureterostomy hole with 4-0 Vicryl. Four weeks later, the D-J stent is removed via cystoscopy.

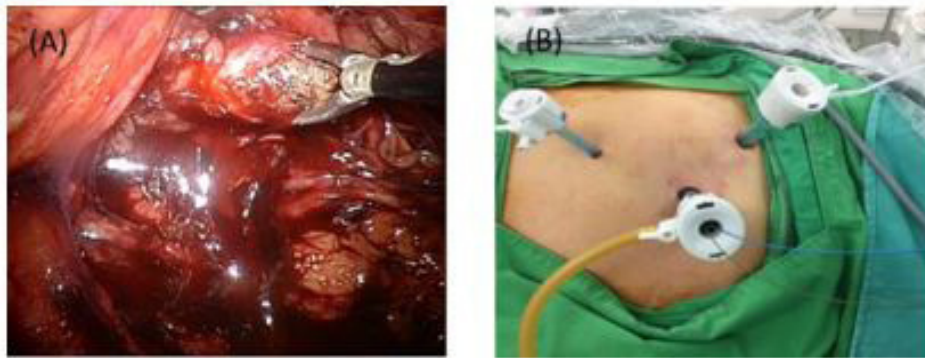

Figure 2: 2A: Ureteral stone was removed. 2B: The metal stents was kept outside the abdomen after pushing D-J stent into peritoneal cavity

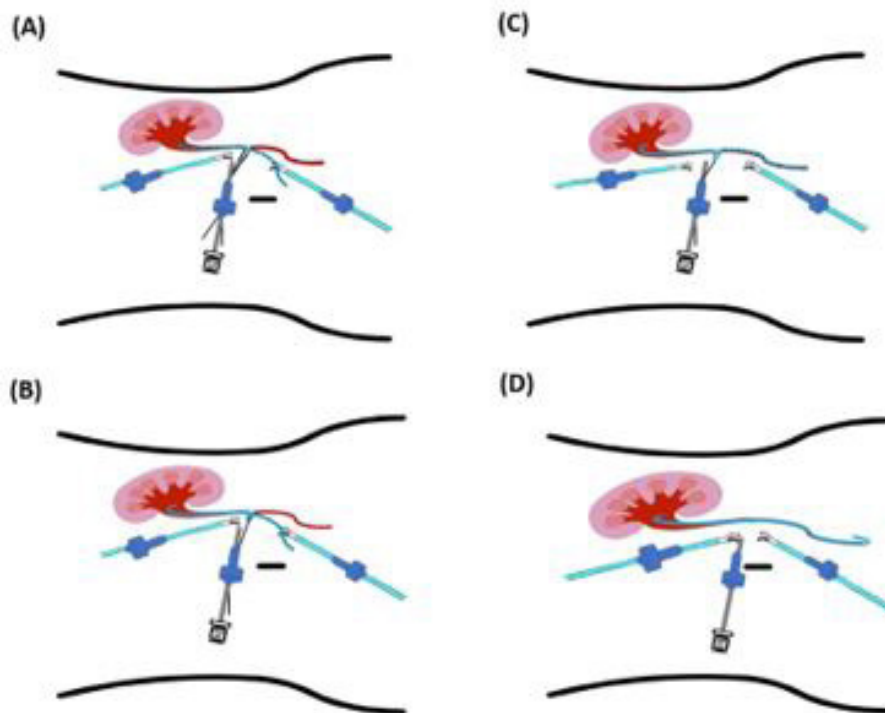


Figure 3: Schematic diagram of a modified D-J stent being introduced into the ureter with antegrade and retrograde technique via the ureteral incision hole using laparoscopic forceps.

3A: insertion of one end of the D-J stent with a metal guidewire into the renal pelvis using laparoscopic forceps. 3B: pull out the metal guidewire and the placement D-J stent within renal pelvis. 3C: insertion of the other end of the modified D-J stent with a guidewire into the bladder using laparoscopic forceps. 3D: pull out the metal guidewire and the placement D-J stent within bladder, then adjustment of the location of the D-J stent in the ureter

Results

From January 2010 to December 2019, sixty patients had received laparoscopic ureterolithotomy using the novel technique to introduce the D-J stent into ureter simultaneously. To date, no patients have had documented postoperative urine leakage or ureteral strictures.

Conclusion

LU is a minimally invasive surgical procedure for impacted and difficult stones in the ureter. The greatest concern during LU is the introduction of a D-J stent into the ureter because the laparoscopic technique of placing the stent is difficult. The D-J stent allows adequate urine drainage to prevent ex-

travasation of urine and to permit good healing of the ureter. Some auxiliary techniques have been described for insertion of a D-J stent, such as flexible ureteroscopy, use of a ureteral access sheath, or cystoscopy with D-J stenting. However, these are time-consuming and expensive. Therefore, we developed this new technique, which facilitates a shortened operative time and avoids added costs. In addition, this procedure requires no special device for placement of a D-J stent.

We present an easily learned, cost-effective method to introduce a D-J stent after removal of ureteral stones during LU. Use of a modified D-J system requires no additional equipment and aids effective placement of a ureteral stent. We think that this novel technique will facilitate the insertion of a D-J stent during LU.

Acknowledgment

We thank all the patients who provided the data and all investigators for their contribution to data acquisition.

References

1. LM Harewood, DR Webb, AJ Pope (1994) Laparoscopic ureterolithotomy: the results of an initial series, and an evaluation of its role in the management of ureteric calculi. *British J urology* 74: 170-6.
2. El-Moula MG, Abdallah A, El-Anany F (2008) Laparoscopic ureterolithotomy: our experience with 74 cases. *Int J Urol* 15: 593-7.
3. Raboy A, Ferzli GS, Ioffreda R (1992) Laparoscopic ureterolithotomy. *Urology* 39: 223-5.
4. Kiyota H, Ikemoto I, Asano K (2001) Retroperitoneoscopic ureterolithotomy for impacted ureteral stone. *Int J Urol* 8: 391-7.
5. Jae Hyung You, Young Gon Kim, Myung Ki Kim (2014) Should we place ureteral stents in retroperitoneal laparoscopic ureterolithotomy?: consideration of surgical techniques and complications. *Korean J Urol* 55: 511-4.

Submit your manuscript to a JScholar journal and benefit from:

- ¶ Convenient online submission
- ¶ Rigorous peer review
- ¶ Immediate publication on acceptance
- ¶ Open access: articles freely available online
- ¶ High visibility within the field
- ¶ Better discount for your subsequent articles

Submit your manuscript at
<http://www.jscholaronline.org/submit-manuscript.php>